FOCAL SPOT

FS



FALL/WINTER 2022 Advancements in Imaging and Treatment of Prostate Cancer

MALLINCKRODT INSTITUTE OF RADIOLOGY // WASHINGTON UNIVERSITY // ST. LOUIS

CONTENTS

Cover Photo: "Dr. Fraum will lead us in increasing the use of PET/MRI in prostate cancer, a very important goal," says Barry A. Siegel, MD.

Left: Fernando R. Gutierrez, MD, professor of radiology and for more than two decades the beating heart of MIR's efforts in Latin America.

FOCAL SPOT MAGAZINE
FALL/WINTER 2022

Editor: Marie Spadoni
Associate Editor: Kristi Luther
Photography: Glennon Williams, MIR Archives
Design: Kim Kania

mir.wustl.edu

As a result of a new team approach, MIR now has the capacity to perform more ambitious biopsies, says Benjamin S. Strnad, MD (above left), who spearheaded the effort.

New Service Line Transforms Deep-Tissue Biopsy Care

by Kristin Rattini

A new service line dedicated exclusively to deep-tissue biopsies is enabling a team of abdominal radiologists at MIR to provide more cohesive, comprehensive and consensus-based care for biopsy patients.

"The new dedicated service line has made the experience more pleasant for patients and the process go a lot more smoothly," says Vincent M. Mellnick, MD, chief of abdominal imaging. The addition of staff, use of sedation for procedures and a dedicated recovery space have ultimately resulted in safer, more robust patient care.

Previously, biopsies were performed as part of normal diagnostic duties and based on modality. For example, an abdominal radiologist on the CT service would perform any CT-guided biopsies in between reading all the CT scans for that day. "There were a lot of inherent distractions associated with that method," says Mellnick, associate professor of radiology. Pre-procedural assessment and post-biopsy monitoring also varied by modality and location.

"We determined that we needed a more organized and formal structure in which to assess, monitor and recover patients in a way that did not rely on the availability and attention of a person who was being pulled in multiple directions at the same time," says Benjamin S. Strnad, MD, assistant professor of radiology. Strnad spearheaded the effort to launch the new service and coordinated key elements with radiology nursing leadership at Barnes-Jewish Hospital during the summer of 2020, when a reduced patient load provided time to strategize.

The new service line that emerged includes eight abdominal radiologists who all rotate on the service. They handle only deep-tissue biopsies of all modalities on the day they are on service and are responsive to any issues during recovery. Recovery is now standardized and occurs in dedicated post-procedural monitoring areas, such as the interventional radiology holding area or the surgical post-anesthesia care unit (PACU). The standard use of intraprocedural nurse monitoring and recovery has also enabled the service to routinely offer conscious sedation.

Two biopsy nurse coordinators were added to the service to facilitate screening of deep-tissue biopsy patients for risk factors and to facilitate medical optimization of higher-risk patients. Two physician assistants joined the service as well and alternate overseeing the daily logistics of the service, including the screening and initial work-up of any inpatient biopsies. They also act as the biopsy team's point person if concerns about complications, particularly internal bleeding, arise during recovery.

The new service line's team has significantly increased communication among its members, who often review biopsy requests together. "If someone has experience with a particularly challenging or unusual biopsy, they'll chime in and say, 'I know how to do this. You can schedule it with me' or 'I don't think we should perform this biopsy and here's why,'" Strnad says. "That consensus approach was not routine prior to this group being formed."

As a result of this team approach, MIR now has the capacity to perform more ambitious biopsies, Strnad says. "We have a greater pool of knowledge and a much more structured and safer environment than we had before."

Training the Next Generation of Radiopharmaceutical Scientists

by Bailey Tripp

Mallinckrodt Institute of Radiology (MIR) is now home to a multidisciplinary initiative to train the next generation of PET molecular imaging scientists. Translational Imaging in Radiopharmaceutical Sciences (TIRS) is a T32 postdoctoral training program funded by the National Institute on Aging. TIRS aims to train scientists to design, develop and translate diagnostic agents for probing different biomarkers mediating pathogenesis of neurodegenerative diseases, including Alzheimer's disease and related dementias.

Thirteen departments across Washington University in St. Louis and the School of Medicine have committed to the cause, bringing together leading scientists from the radiological sciences division of MIR, Knight Alzheimer's Disease Research Center, Molecular Imaging Center, Institute of Clinical and Translational Sciences, Cyclotron Facility and PET Radiotracer Translation and Resource Center on a single platform to train PET molecular imaging scientists. Vijay Sharma, PhD, professor of radiology, is the principal investigator of the T32 grant and co-directs the program with Tammie L.S. Benzinger, MD, PhD, professor of radiology, and Zhude (Will) Tu, PhD, professor of radiology.

"I cannot think of a better place than MIR to launch this program," says Sharma, noting MIR's standing at the forefront of translational research. The idea for a dedicated radiopharmaceutical postdoctoral training program was conceived after a discussion about the nationwide workforce shortage of radiochemists and its impact on health-care science. Sharma wanted to build a training program geared toward PET radiopharmaceuticals, from conception to the development and ultimate translation into the clinic. He sees it as a crucial bridge in addressing the immediate need for molecular imaging scientists, as well as a possible long-term imaging workforce pipeline, thus ultimately preparing trainees for faculty positions in diagnostic nuclear medicine and in neuroscience.

Recruitment of the first cohort of trainees is already underway. The program will have three postdoctoral trainees each year, with each trainee enrolled for two years over the five-year T32 grant. All trainees are provided multidisciplinary dual mentorship (one mentor in basic science and one physician-scientist), with mentors ranging from chemists to immunologists, neurologists to radiologists.

Sharma initially had 30 colleagues in mind to serve as program mentors; by the time he submitted the grant, 60 faculty members had committed to join the T32 TIRS program. He notes that the willingness of his peers and various departments to commit to this effort highlights both the need for this type of program and the university's collaborative culture.

Vijay Sharma, PhD (below right), principal investigator of the T32 grant, says it is "the most unique program of its kind in the country."

SPOT NEWS

Biomarkers for Parkinson's Disease Sought Through Imaging

by Beth Miller

A team of researchers led by Abhinav Jha, PhD (above left), developed a method to measure dopamine transporter through SPECT.

A team of engineers, physicians and researchers at Washington University in St. Louis, led by Abhinav K. Jha, PhD, assistant professor of radiology and of biomedical engineering, has collaborated to create an imaging method that allows them to get an accurate measurement of dopamine transporter, a protein important in movement, in three regions in the brain associated with Parkinson's disease. Results of their research appeared in Medical Physics, published in August 2022.

While most studies on developing biomarkers for Parkinson's disease have focused on measuring the dopamine transporter uptake within caudate and putamen, such measures may only correlate with severity in early Parkinson's disease. That leaves an important need for biomarkers that can measure the severity throughout the range of the disease. To reach this goal, Joel S. Perlmutter, MD, the Elliot H. Stein Family Professor of Neurology and a preeminent physician and researcher in Parkinson's disease, encouraged Jha to determine if the dopamine transporter uptake within the globus pallidus could serve as a biomarker.

Measuring dopamine transporter uptake within the caudate, putamen and globus pallidus from SPECT imaging requires that these regions are delineated accurately. However, delineating these regions on these images is challenging because of limited SPECT system resolution, which results in blurred boundaries of the regions, as well as finite voxel — similar to pixels in a digital image — size, which leads to voxels containing a mixture of regions. These limitations become even more prominent due to the small size of these regions. In particular, the globus pallidus is nearly impossible to delineate on a SPECT image by the naked eye, and there are no validated tools available for this purpose. Jha and the team developed a method to address these challenges. This will now provide the tools to determine if measurement in the globus pallidus will help serve as a measure of disease severity.

Last year, Jha and Ziping Liu, a doctoral student in his lab, published a paper where they used estimation theory and deep learning to differentiate a tumor from normal tissue in PET images. The method outperformed existing methods and more accurately differentiated tumors from normal tissue even when the tumor was small. Liu advanced on the methodology developed in that work to address the challenge of delineating the dopamine transporter SPECT images.

A key advance was to recognize that while these regions are difficult to see on SPECT images, they are easier to delineate on MR images. Jha and Liu developed an approach that could transfer this knowledge learned from MR images to delineate SPECT images.

"Evaluation of the developed method using clinically realistic simulation studies shows that the method accurately segmented the caudate, putamen and globus pallidus and significantly outperformed multiple other methods, including state-of-the-art deep learning approaches," Jha says. Ultimately, the team demonstrated reliable quantification of the dopamine transporter uptake within the caudate, putamen and globus pallidus regions.

"This opens up a new and important research frontier on evaluating the functional characteristics of the globus pallidus in patients with Parkinson's disease," Jha says. "All of these studies may lead to new biomarkers for measuring the severity of Parkinson's disease and possibly for differential diagnosis of the disease."

"This project leads the way to developing new measures of Parkinson disease severity," says Perlmutter, also a professor of radiology, of neuroscience, of physical therapy and of occupational therapy. "Such measures are critically important to development of new treatments to slow disease progression."

Study Yields Clues to Understanding Alzheimer's Disease

by Tamara Bhandari

A recent study, published Nov. 16 in Science Translational Medicine, yields clues to why certain parts of the brain are particularly vulnerable to Alzheimer's damage. It comes down to the gene APOE, the greatest genetic risk factor for Alzheimer's disease. The parts of the brain where APOE is most active are the areas that sustain the most damage, the study found. The findings help explain why symptoms of Alzheimer's disease sometimes vary and highlight an understudied aspect of Alzheimer's disease that suggests yet-to-be discovered biological mechanisms may play an important role in the disease.

"There are some rare, atypical forms of Alzheimer's in which people first develop language or vision problems rather than memory problems," says senior author Brian A. Gordon, PhD, an assistant professor of radiology. "When you scan their brains, you see damage to the language or the visual areas, and not so much to the memory areas. People with atypical Alzheimer's are often screened out of research studies because it's easier to study a group where everyone has the same set of symptoms. But this heterogeneity tells us that there are things we still don't understand about how and why Alzheimer's develops the way it does. There's a reason why certain brain areas become damaged and not others, and we don't know that reason yet. Every mystery we uncover with this disease pushes us closer to what we need to address it."

To understand why Alzheimer's brain damage occurs where it does, Gordon and colleagues studied 350 people who volunteer for memory and aging studies through the Washington University School of Medicine's Charles F. and Joanne Knight Alzheimer Disease Research Center. The participants underwent brain scans so the researchers could measure the amount and location of amyloid plaques and tau tangles, and the volumes of various brain areas.

The researchers compared the patterns of protein clumps and tissue damage in the volunteers to the gene expression patterns of APOE and other genes associated with Alzheimer's disease as depicted in the Allen Human Brain Atlas, a detailed map of gene expression in the human brain compiled by the Allen Institute for Brain Sciences.

"There was a close match between where you see high APOE expression, and where you see tau tangles and tissue damage," says Gordon. "And not just APOE. If you look at, say, the top 20 genes associated with Alzheimer's disease, they are all expressed in the temporal lobes in similar patterns. There's something fundamentally different about these regions that make them vulnerable to Alzheimer's brain damage, and that difference is probably baked in from birth and influenced by a person's genetics."

Everyone carries some version of the APOE gene, but people who carry the APOE4 variant are up to 12 times more likely to develop Alzheimer's disease than the general population, and at a younger age. "APOE4 carriers are more likely to start accumulating amyloid, which puts them on the path to Alzheimer's," Gordon says. "Then, for the same amount of amyloid they get more tau tangles, which leads to more atrophy. It's a double hit on the brain."

In future work, Gordon and colleagues plan to explore how patterns of gene expression relate to patterns of tau damage in people with atypical Alzheimer's.

"When we see someone who presents with vision problems, is there a specific genetic signature that corresponds to the areas that are damaged in the brain?" Gordon asked. "We want to know why some people have these altered patterns and what it means about how Alzheimer's disease develops and how it can be treated."

Findings from a recent study could help explain rare, atypical forms of Alzheimer's, says senior author Brian Gordon, PhD.



RSNA 2022:
Connecting in Chicago

MIR faculty, staff and trainees joined nearly 38,000 of their radiology peers at RSNA 2022, the 108th Scientific Assembly and Annual Meeting, at Chicago's McCormick Place. With the theme of "Empowering Patients and Partners in Care," the program emphasized the importance of empathy, diversity and equity in health care. In addition to presenting innovations in radiological sciences and valuable clinical insights, several MIR faculty members were honored with awards for their impactful work in patient care, research and education.

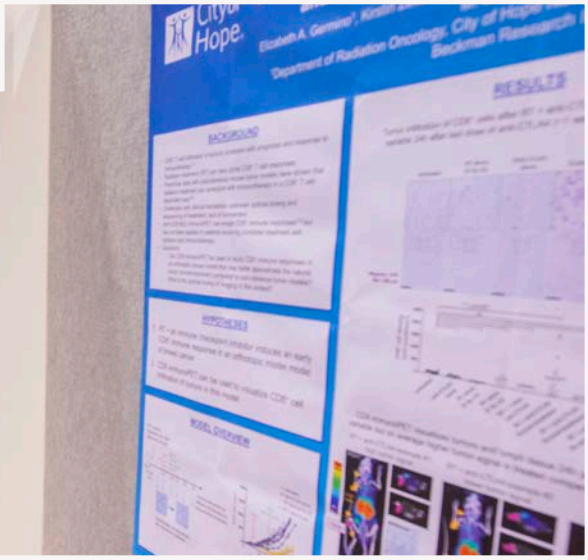



Culver Named Distinguished Investigator

Joseph P. Culver, PhD, the Sherwood Moore Professor of Radiology, has received the Distinguished Investigator Award from the Academy for Radiology & Biomedical Imaging Research. Culver's work has been at the leading edge of functional and molecular biological imaging, particularly in leveraging noninvasive optical measurements and advancing diffuse optical tomography (DOT) technology.

Established in 2012, the Distinguished Investigator Award honors those who've made outstanding contributions to medical imaging and celebrates excellence in academic imaging research, especially those who achieved scientific excellence while still being involved in clinical care.

Balfe Receives Outstanding Educator Award

Dennis M. Balfe, MD, professor emeritus of radiology, was honored with the RSNA Outstanding Educator Award. This award recognizes pioneers in their specialty who've made significant contributions to radiologic education. The RSNA board of directors selects one recipient each year that they believe best exemplifies long-term commitment to the field.

Balfe is a revered educator who mentored countless trainees during his four-decade career at Washington University School of Medicine in St. Louis, including his time as MIR's radiology residency program director from 1992 to 2006. He received MIR's Distinguished Teaching Award multiple times throughout his career.

MIR's Annual RSNA Reception

Every year, the MIR network converges at the Hyatt Regency of Chicago's Crystal Ballroom for great food and conversation as they reconnect with current and former faculty and trainees. Traveling from all corners of the globe, attendees also receive an update from Director Richard L. Wahl, MD, on MIR's latest developments — from grant funding and national recognition, to clinical advances and new equipment.


SIEMENS
Healthineers
Washington University in St. Louis
Physicians
Tyler Fraum, MD

by Pam McGrath

Breakthroughs in Prostate Cancer

Advancements in Imaging and the Evolution of Theranostics

In the early 1990s, nuclear medicine researchers began working to develop a radioactive tracer that effectively identified prostate cancer metastasis. But it was a goal more easily stated than achieved.

"Since prostate cancer's metastatic disease often spreads to bone, for decades conventional radionuclide bone scans were standard of care for staging and restaging men with prostate cancer," says Barry A. Siegel, MD, professor of radiology.

Metastatic prostate cancer isn't limited to bones, however, often traveling to lymph nodes and sometimes organs such as the liver and lungs. Conventional imaging with CT or MRI has limited accuracy for detecting these metastases. How to identify lesions throughout the body became a quest

Opposite: Barry A. Siegel, MD (left), Tyler J. Fraum, MD (center), and Farrokh Dehdashti, MD (right), have all contributed to MIR's history of advancing prostate cancer research and care.

that resulted in multiple radioactive tracers being developed through the years, all with limited success.

"MIR was an early adopter of ProstaScint, the first prostate cancer imaging agent approved by the FDA in 1999, and we have been heavily engaged in research and pivotal clinical trials since then," says Siegel, who led the division of nuclear medicine from 1973 to 2017.

That research included studies in the early 2000s using PET with 11C-acetate for the initial staging of men with newly diagnosed, high-risk prostate cancer. In November 2014, MIR received U.S. Food and Drug Administration (FDA) approval to use 11C-choline with PET/CT and PET/MRI to detect biochemical recurrence of prostate cancer. MIR also participated in the LOCATE study, which showed the clinical impact of Axumin (18F-fluciclovine), another radiopharmaceutical for PET that was approved by the FDA in 2016. Axumin is indicated for PET imaging for men with suspected prostate cancer recurrence based on elevated prostate-specific antigen (PSA) levels following prior treatment.

"We are basically reinventing how we stage prostate cancer."

"These studies and others in which we participated had some success in imaging prostate cancer, but none of them produced images that gave us total confidence we were identifying all of our patients' metastatic lesions," says Siegel. Then, in 2020 and 2021, drugs targeting prostate-specific membrane antigen (PSMA) lesions in men with prostate cancer were approved by the FDA. Siegel and his colleagues describe these PSMA-targeted PET imaging drugs as "revolutionary" in the quality of images produced and potentially for how patients with prostate cancer will receive treatment in the future.

Understanding the Role of PSMA

All prostate cells contain low levels of PSMA, a protein that rests mainly on the cell surface. Both PSMA and another protein, prostate-specific antigen (PSA), become elevated when cancer is present. Until recently, it wasn't known what role PSMA played in prostate cancer development; new research indicates it indirectly activates a cancer-causing pathway involving a protein kinase.

"These new PET agents bind to PSMA, which is easily accessible on the surface of prostate cancer cells," says Tyler J. Fraum, MD, assistant professor of radiology. "The FDA approved them for use in patients with newly diagnosed high-risk prostate cancer that may be curable with surgery or other therapies, as well as in patients suspected of having recurrent prostate cancer based on elevated PSA levels."

MIR played a significant role in trials evaluating Pylarify (18F-piflufolastat) for FDA approval, serving as a lead enroller of patients in its OSPREY and CONDOR clinical trials. Siegel was a senior author on papers summarizing the clinical trials' findings.

"The studies showed that these PSMA-targeted drugs identify far more prostate cancer lesions than any other tracers used in the past," says Siegel. "The result is, we are basically reinventing how we stage prostate cancer, both initially and at the time of recurrence, because we are finding disease we had no knowledge of previously."

This means patients may be identified as having a higher stage of cancer than initially diagnosed — for instance, stage 1 may now be classified as stage 2, stage 3 may be stage 4. "Additional study needs to be done to determine the impact of this stage migration on patient outcomes, as well as to decide whether prostate cancer treatments need to be changed to address the new information these improved scans are providing," says Siegel.

MIR has played a significant role in evaluating newer PET agents that detect more prostate cancer lesions than previous agents.

The Advent of Theranostics

The new drugs also make possible the integration of therapy and diagnostics in nuclear medicine, according to Farrokh Dehdashti, MD, the Drs. Barry A. and Marilyn J. Siegel Professor of Radiology and senior vice chair and division director of nuclear medicine. Called theranostics, this combination focuses on patient-centered care that provides treatment based on whether a patient's cancer demonstrates affinity for the diagnostic form of a drug.

"Theranostics basically means we treat what we see," she says. "The first step is tagging a PSMA-targeted drug with a diagnostic agent to identify metastatic prostate cancer lesions. If we determine the patient will benefit from treatment, the second step is tagging the same drug with a therapeutic radioactive agent that delivers a dose of radiation specifically to the area where lesions are overexpressing PSMA. Since the therapy is targeted specifically to the PSMA on prostate cancer cells, surrounding tissues are less likely to be affected by the therapy."

PET/MRI: A Combined Advantage

PSMA-targeted PET imaging drugs will play a role in a project under development by Fraum as well. With training in both diagnostic radiology magnetic resonance imaging (MRI) and nuclear medicine PET imaging, Fraum interprets both PSMA PET scans and prostate MRIs conducted in abdominal imaging. He is using this dual expertise to expand MIR's capabilities in offering the hybrid imaging modality of PET/MRI scans.

"Patients with newly diagnosed or biochemically recurrent prostate cancer often undergo both MRI and PET scans," says Fraum. "The MRI identifies the local extent of disease, whereas the PSMA PET is most useful for identifying regional nodal or distant sites of cancer spread."

PET/MRI combines both scans into a single examination, a one-stop shop for patients. It has significant advantages from an interpretive perspective too.

"PET/MRI enables us to see more precisely the correlation between findings on those two separate examinations in a way that's not always possible if they are conducted at different times," explains Fraum. "Structures in the pelvis can shift — for example, the bladder filling and emptying — and it's not always clear when looking at the two scans performed separately whether a finding of concern on one study corresponds with the same finding of concern on the other. When PET and MRI are done at the same time, we have near-perfect co-registration of those images."

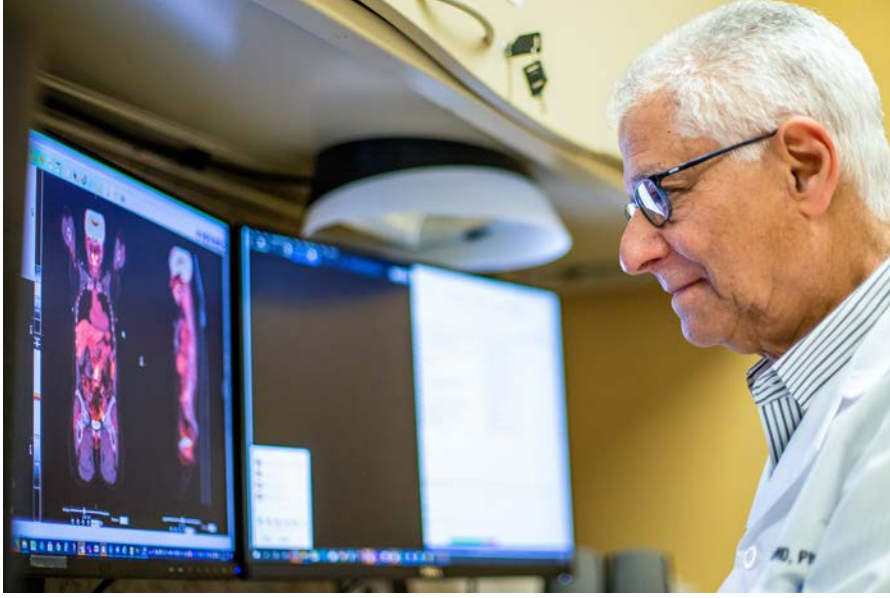

Siegel describes PSMA-targeted PET imaging drugs as "revolutionary" in the quality of images produced.

The Nuclear Medicine Evolution Continues

Even with significant advancements such as PSMA-targeted PET imaging drugs, investigators continue to explore ways to improve the technology.

"There are new PSMA tracers in the development pipeline that may perform even better than the tracers currently available to us," says Fraum. "An example is a PSMA tracer that doesn't undergo as much urinary excretion. Tracer in the urinary bladder can interfere with the detection of prostate cancer in the pelvis."

Although MIR's Division of Nuclear Medicine historically has concentrated on the diagnostic aspect of theranostics, Dehdashti notes that upcoming clinical trials will focus on the division administering the therapeutic dose as well. She adds, "And we will continue participating in nuclear medicine imaging clinical trials that we feel best serve our patient population."

Siegel sees the division's decades-long history of research into prostate cancer imaging as an evolution. "We moved from tests that weren't as useful as we hoped they would be to the tests available today that are changing the way we diagnose and treat the disease. It's gratifying to be able to provide information that significantly impacts how patients are managed."

La Magia de MIR

Gutierrez Brings Radiology Education to Latin America

Cuba native Fernando R. Gutierrez, MD, works tirelessly to give the radiological community in Latin America access to some of the quality educational opportunities and resources available at MIR.

by Kristi Luther

From Lima, Peru, to the Patagonia region of Argentina, faculty members of Mallinckrodt Institute of Radiology (MIR) are warmly welcomed as guest speakers by packed rooms of Latin radiologists hungry to learn from MIR subspecialists. In fact, presentations by MIR radiologists regularly draw standing-room-only crowds in cities like Cartagena and Buenos Aires.

Sanjeev Bhalla, MD (right), has been engaged with Gutierrez's efforts in Latin America for more than two decades.

In February 2022, a team from MIR was the first to be welcomed as the exclusive speakers at the Radiological Society of Puerto Rico's annual meeting. The MIR radiologists presented a variety of lectures on cardiothoracic imaging, musculoskeletal radiology, abdominal radiology and neuroradiology to a rapt audience. For more than two decades, these MIR radiology experts have been mobilized by Fernando R. Gutierrez, MD, professor of radiology and the beating heart of MIR's efforts in Latin America.

As a faculty member in the late 1990s, Gutierrez felt MIR could be doing more to disseminate its impressive breadth of radiology knowledge and innovation worldwide. "I thought Mallinckrodt had done a great job within the U.S," says Gutierrez, who arrived in the U.S. with his family from Cuba at age 13. "But outside of here, especially in Latin America, it was not well known."

So he hit the road, forging connections with leaders of Latin American radiological societies, which eventually prompted invites for him to speak at annual national meetings. And not only would Gutierrez go; he would bring a subspecialized MIR colleague with him.

The Magic of MIR

During his fellowship, Gutierrez recognized firsthand the exceptional talent and deep knowledge that MIR brought to the field of radiology. He recalls feeling the "magic" of MIR as told to him by Larry P. Elliott, MD, former head of what is now the cardiothoracic imaging section and who passed away in 2016. "Larry told me that of all the places he had been, the only place where he felt that the walls would vibrate was Mallinckrodt because there was so much going on: research, teaching, excellent medical care. That was one of the reasons why I stayed on here — because I started to feel that vibration."

Gutierrez's collaborations, like the one with Puerto Rico, have laid the groundwork for MIR's widespread impact across Latin America. "Fernando is the best and most important mentor of my professional career," says Gory Ballester, MD, president of the Radiological Society of Puerto Rico. Gutierrez helped Ballester coordinate a three-month rotation in cardiac imaging at MIR at a time when nobody was doing cardiac imaging in his native Puerto Rico. "Fernando and MIR have served as a perfect duo to develop many radiologists from all over the world. This has had the effect of dispersing 'seeds' that grow with their lead and later emulate Fernando and the lessons learned at MIR." And Gutierrez has planted these "seeds" throughout Latin America — in Argentina, Chile, Colombia, Mexico, Peru, Puerto Rico and beyond.

> "Fernando often says a great teacher can teach anyone in any language."

Sanjeev Bhalla, MD, chief of cardiothoracic imaging, has been engaged with Gutierrez's efforts in Latin America for more than two decades, both traveling abroad as well as educating residents who rotate through MIR's training program at Washington University School of Medicine in St. Louis. As a fluent Spanish speaker, Bhalla, along with Maria Rosana Ponisio, MD, and Gloria J. Guzmán Pérez-Carrillo, MD, have the added benefit of interacting with meeting attendees and trainees in their native language. But even MIR team members who speak only English have had great success in educating abroad with the use of translation tools.

"These efforts have made me and my colleagues better teachers," says Bhalla. "Fernando often says a great teacher can teach anyone in any language. The essence of this statement is that a good teacher learns to distill the key point and use words sparingly."

In addition to the national meetings, Gutierrez has helmed a three-decades-long rotation program that hosts from two to four residents each year from Santiago, Chile. The program is fueled by a strong collaboration with the residency program at Catholic University Clinical Hospital in Santiago, led by MIR alumnus Alvaro Huete, MD. Although the COVID-19 pandemic has disrupted the program, there are hopes to resume once it's feasible to do so.

"Of all the universities in the U.S., you would think our radiology colleagues in Latin America would probably have the best relationship with institutions in San Diego, Miami, Boston," says Gutierrez. "That would make sense on paper. But it's not. It's Mallinckrodt in St. Louis."

Gutierrez and his colleagues often assist with educational placements worldwide.

Gutierrez and colleagues not only advocate for trainees to experience MIR firsthand; they also frequently assist with educational placements worldwide. He recalls a trainee who wanted to complete a mini-fellowship at MIR in hopes of bringing subspecialized cardiothoracic imaging care to his native Cuba. But political roadblocks proved difficult, so Gutierrez and Bhalla got creative, coordinating a fellowship in Argentina with another member of the MIR family, Santiago Rossi, MD.

Filling Gaps Using a Multipronged Approach

Situations like these illuminate gaps that Gutierrez is passionate about filling. In an editorial published in the Spanish journal Radiología, he discussed a few key deficits facing many Latin American radiology training programs. For example, some high-quality programs lack a strong diversity of pathology, as they are centered in private-practice settings. In contrast, programs set in public or university hospitals have exposure to this diversity of pathology but are often staffed with fewer subspecialized radiologists and do not possess state-of-the-art imaging equipment. These programs also tend to use a three-year training model — which Gutierrez finds to provide insufficient time to adequately explore current and emerging imaging modalities — and they also lack opportunities for study abroad.

When it comes to spreading MIR's knowledge and making a dent in these gaps, Gutierrez has no intention of slowing down in the near future — especially now that he has scaled back to working part time, freeing up more hours for his international endeavors. He already has plans to attend meetings in Cuba, Costa Rica, the Dominican Republic, Panama and Argentina in 2023. In the meantime, Gutierrez takes advantage of the Radiological Society of North America's annual meeting to connect with peers worldwide. Bhalla and MIR alumna Cooky O. Menias, MD, a professor of radiology in the abdominal radiology section at Mayo Clinic College of Medicine and Science, organize an annual dinner at RSNA celebrating the numerous connections made with counterparts in Latin America as a result of their efforts alongside Gutierrez. They wanted to give back as a means of honoring the exceptional treatment they receive when traveling abroad and extending the MIR network.

"It's an ever-growing family," says Gutierrez. "We plant the seed, and it keeps on growing like a weed — a good weed."

Top: Gory Ballester, MD (left), has been a consistent collaborator of Gutierrez (right). "Fernando is like an ambassador of MIR to Latin America," says Ballester, president of the Radiological Society of Puerto Rico.

Bottom: MIR faculty members from various clinical sections presented educational lectures to fellow radiologists in the Patagonia region of Argentina in the fall of 2022.


Radiological

Sex Differences

MIR Research Provides Powerful Insights

by Kristi Luther

Robert J. Gropler, MD, senior vice chair and division director of radiological sciences, recalls a time in 2007 when he and collaborators were wondering whether biological sex differences in myocardial metabolism were worth exploring in their research. "Pilar Herrero came into our office and kept saying, 'There's something here,'" Gropler says. Herrero, who since passed away, specialized in quantitative imaging analytics and modeling of cardiac PET images. "She felt strongly there was something to learn from studying males and females. It took a lot of work to find an answer, but it turns out the answer is yes, there is."

Joseph Ippolito, MD, PhD (left), postdoctoral research associate Jasmin Sponagel, PhD (right), and collaborators explored whether biological sex underlies differences in brain tumor glutamine metabolism.

In 2019, Manu S. Goyal, MD (above), found that female brains appear to be about three years younger than male brains of the same age.

Sex differences are illuminating a potentially powerful strategy in the advancement of personalized medicine and the fight against disease. While developing new therapies and drugs remains a key aspect of advancing personalized medicine, those paths also require years and countless dollars. Instead, understanding sex differences could help MIR researchers make a more immediate impact by allowing existing therapies to be optimized more precisely and trials to be structured more effectively.

"I think MIR is leading the way on this in many areas," says Gropler, a professor of radiology. Broadly speaking, research has shown that healthy males are more dependent on sugars and amino acids for cellular metabolism in various organs, while females are more dependent on fatty acids. MIR researchers are working to better understand these sex differences in normal cellular metabolism, which could provide powerful insights into how various diseases — such as different types of cancers and cardiovascular disease — can be treated.

An Invariably Lethal Disease

In 2022, a team of researchers investigated glioblastoma (GBM) — an aggressive, fast-growing cancer and the most common malignant brain tumor in adults. Recognizing GBM as "an invariably lethal disease," Joseph E. Ippolito, MD, PhD, associate professor of radiology, and collaborators set out to explore whether biological sex may underlie differences in brain tumor glutamine metabolism, a hallmark of cancer development.

Rivaling GBM's lethality is its elusiveness. Jasmin Sponagel, PhD, a postdoctoral research associate and lead author of the research team's paper, felt compelled to study glioblastoma considering the last major advancement was when Temozolomide was added as a chemotherapeutic — over 20 years ago.

The collaboration between the Ippolito Lab; the Rubin Lab, led by Joshua B. Rubin, MD, PhD, professor of pediatrics; the Patti Lab, led by Gary J. Patti, PhD, the Michael and Tana Powell Professor of Chemistry; as well as counterparts at Memorial Sloan Kettering Cancer Center consisted of a metabolite abundance assessment in a previously published dataset of 757 metabolites in 44 male and 32 female, newly diagnosed GBM surgical specimens.

In diabetic patients, females have a higher instance of cardiovascular complications and incidence of heart failure.

The findings were published in a paper titled "Sex differences in brain tumor glutamine metabolism reveal sex-specific vulnerabilities to treatment" in Med by Cell Press. Ultimately, the team found there were clinically important sex differences in targetable elements of metabolism, indicating that more research recognizing sex-based metabolism could illuminate ways to improve current treatments for this notoriously aggressive cancer. Previous GBM research highlighted the significance of sex-based differences: males are 60% more likely to develop GBM than females; and females respond better to therapy, resulting in a notably longer survival rate.

Further accentuating the impact of sex differences across pathologies, Ippolito and Sponagel also recently studied glucose metabolism in lung cancer, the leading cause of cancer-related death. In a similar fashion to brain tumors, males have a higher lung cancer mortality rate than females, and the researchers disovered that male lung cancers utilize glucose to supply tumorigenesis to a greater extent than female tumors.

Ippolito emphasizes that considering how the trio of chromosomes, epigenetics and sex hormones play into cancer biology may be a catalyst for precision medicine. "I think what we're getting at here is advancing personalized medicine," he says. "We're starting with looking at sex."

Seeing the Same Thing

The GBM study builds on an expansive history of research on sex differences at MIR. Gropler's team — in collaboration with Linda R. Peterson, MD, professor of medicine and radiology — found that healthy normal females are more dependent on fatty acids for their cardiac metabolism, while males are more dependent on glucose. Females also had higher blood flow and oxygen consumption and were slightly less efficient in their heart work than the males.

"And that's just among normal volunteers," Gropler says. "We then took those findings and showed that pattern persisted through multiple diseases, including heart failure, dilated cardiomyopathy, obesity and diabetes, and was a key determinant of how these diseases impacted the heart."

In diabetic patients, females have higher incidences of cardiovascular complications and heart failure. "It turns out, with diabetes mellitus, it forces the heart to use more fats as opposed to glucose," Gropler says. This becomes magnified in females due to their underlying increased reliance on fatty acid metabolism.

> "I think the most immediate dream for future clinical approaches would be to actually consider sex in a clinical setting."

Similar findings regarding sex differences extend across MIR's research enterprise, including research on brain metabolism that determined "brain age." In 2019, Manu S. Goyal, MD, associate professor of radiology, alongside MIR collaborators Marcus E. Raichle, MD, and Andrei G. Vlassenko, MD, PhD, found that from a metabolic perspective, female brains appear to be about three years younger than male brains of the same chronological age. The relative youthfulness of female brains was found even in the youngest participants in their 20s. And Ippolito previously showed that abdominal visceral fat affects the odds of women surviving kidney cancer as well as lymphoma, but not for men.

"We're all seeing the same thing with sex differences," says Gropler. "Manu saw the same thing, Joe saw the same thing — all in different areas, in different organs."

Without Looking at Sex, You Might Miss Something

Clinical studies have historically centered on males and do not consistently or adequately capture data on biological sex differences. "I think the most immediate dream for future clinical approaches would be to actually consider sex in a clinical setting," Sponagel says. "If you merge everyone together, you're going to lose valuable results."

Gropler learned this firsthand when he and colleagues were studying diabetic medications and how they impacted metabolism in Type 2 diabetes mellitus. With male and female data pooled, the research team didn't see any differences. Once they included sex differences, however, it became clear that therapeutic regimens impact myocardial metabolism and diastolic function differently in males than in females.

Two things can happen when you leave out sex differences as a factor in preclinical and clinical studies, Gropler says. "One, you may underestimate the disease in one of the two sexes. Or worse yet, you may come to the conclusion that there is no effect. Without looking at sex, you might miss something really important."



"We're all seeing the same thing with sex differences —all in different areas, in different organs," says Robert J. Gropler, MD, senior vice chair and division director of radiological sciences.

Alumni Spotlight

Members of the 2012 residency class are advancing radiology across the country, both in academic radiology and private practice. We checked in with three Class of 2012 alumni to reminisce on their training days and see what they're up to now: Amy M. Fowler, MD, PhD, associate professor of radiology at University of Wisconsin School of Medicine and Public Health; Clinton E. Jokerst, MD, associate professor of radiology at Mayo Clinic College of Medicine and Science in Phoenix; and Luke L. Linscott, MD, pediatric and neuroradiologist at Intermountain Healthcare in Salt Lake City.

Why did you choose MIR for your residency training?

Jokerst: I was in medical school and had shifted my interests from urology to radiology. Due to a bad experience, I was about to switch back to urology, but someone told me about the fantastic radiology training program at Mallinckrodt. I was able to do a fourth-year rotation, and I had such a good experience that I decided that not only did I want to do radiology, I wanted to do radiology at MIR.

Linscott: MIR offered a depth and breadth of radiology training that I hadn't seen before on the interview trail. St. Louis was a great place for our young family.

How would you describe your time at MIR?

Fowler: My time at MIR was the most memorable part of all my years of training. I enjoyed many parts of St. Louis in my free time: exploring the parks; watching comedians at the Fox, Pageant and Peabody theaters; listening to the St. Louis Symphony Orchestra at Powell Hall; and seeing Chuck Berry at Blueberry Hill.

Fowler, now at University of Wisconsin–Madison, says her time at MIR trained her well as an academic radiologist, breast imager and researcher.

Jokerst: Easily some of the best years of my life. Trials and tribulations for sure, but the place is predicated on churning out great radiologists and it shows. When you come out of MIR, you're ready to go. It made the transition into being in the "real world" super easy.

Did any faculty members leave a particularly strong impression on you? Any specific experiences/lessons that carried with you beyond MIR?

Fowler: Barb Monsees and Kate Appleton helped train me as a breast imaging radiologist. They provided excellent patient care and are amazing leaders in the field.

Jokerst: Sanjeev Bhalla and Cooky Menias are probably at the top of the list, and Sanjeev is the reason I'm a cardiothoracic radiologist.

Linscott: Bob McKinstry was a great mentor. Gheetika Khanna, Bill McAlister, Becky Hulett and Steve Don helped guide me to pediatric radiology. Franz Wippold, Josh Shimony, Katie Vo, Michelle Miller-Thomas, Aseem Sharma and Matt Parsons helped develop my interest in neuroimaging as they made rounds in the ever-spacious neuro reading room.

Jokerst enjoys the outdoors by metal detecting for gold, a hobby he took up during the pandemic.

What are some highlights from your residency class ('12)? Any memories, co-residents, etc. that stand out from your MIR experience?

Fowler: I love my residency class; they all stand out as friendly, smart, funny, dependable and hardworking individuals. Co-residents and lifelong friends Sara Dyrstad and Gretchen Smith were awesome to also work with as breast imaging fellows. Many thanks to my co-chief residents Clint Jokerst and Doug Kitchin, who made that job a lot of fun.

Jokerst: I love my class and every single person in it. Everybody is so laid back and has their own quirky personality. Part of the magic of MIR is picking good trainees, and I think Janice Semenkovich was on her game for the class of 2012.

Linscott: The 2012 class was a pretty cool group of humans. Many long evenings of post-work oral board review in the small conference room truly brought us together. I remember carpooling to work with Jared Allen, going through hundreds of post-op ortho films in the salt mines of the CAM on the MSK rotation, and loving the family picnic at the Hulett Farm.

In what way did your training at MIR prepare you for your career path?

Fowler: MIR trained me well as an academic radiologist, breast imager and researcher. It also taught me leadership skills and how to handle stressful situations.

Chief residents Amy Fowler, Clinton Jokerst and Doug Kitchin hold their certificates next to then-MIR Director Gilbert Jost during the 2012 residency graduation ceremony.

One of the activities Linscott enjoys is backcountry skiing in the mountains with friends and family.

Linscott: MIR instilled in me a strong work ethic and the tools to keep learning every day. Nearly every day in my pediatric neuroradiology practice, I see something new — the learning never stops.

What are some of your interests beyond radiology?

Fowler: I enjoy unwinding with family and friends, British detective shows, gardening and, most recently, Wordle.

Jokerst: Getting outdoors, fishing (especially fly fishing for trout) and gold prospecting with a metal detector.

Linscott: There's nothing I love more than spending time with family and friends, preferably in the mountains or the desert. My favorite activities are backcountry skiing, mountain biking and trail running.

Join the MIR Team

MIR is currently looking for radiologists to join our expanding community radiology section in the greater St. Louis area. Candidates with subspecialty training in breast, body and/or musculoskeletal imaging will be highly competitive for these positions. To learn more about open faculty positions at MIR, visit:

facultyopportunities.wustl.edu.

Evens Society Alumni Weekend

The second Evens Society Alumni Weekend, held September 10-11 at the Chase Park Plaza in St. Louis, was by all accounts a huge success. Nearly 200 attendees greeted colleagues and classmates from years past. Weekend events began Friday evening with a welcome reception at the top of the Chase. Saturday kicked off with CME lectures, followed by lunch and afternoon tours of MIR's campus. But the jewel in the weekend's crown was Saturday evening's gala dinner and Evens Society Honors. Shortly after dessert, MIR Director Richard L. Wahl, MD, and Vice Chair of Education Sanjeev Bhalla, MD, took the stage to welcome guests and offer introductory remarks for each of the evening's six legendary honorees (see below). All in all, the weekend was a testament to the lasting legacy of MIR and the joys of "coming home."

Below: The 2022 Evens Society Honorees were (from top left) Joseph K.T. Lee, MD; M. Victoria Marx, MD; William H. McAlister, MD; Emily L. Smith, MD; and Christine (Cooky) O. Menias, MD. **Right**: Honoree Howard P. Forman, MD, was unable to attend the event but sent a heartwarming video acceptance.



FYI

New Hires

Scott M. Bugenhagen, MD, PhD
Assistant Professor of Radiology

Aisling Chaney, PhD
Assistant Professor of Radiology

Gyu Seong Heo, PhD
Instructor in Radiology

Nicole S. McKay, PhD
Instructor in Radiology

Ashwin Singh Parihar, MD
Instructor in Radiology

Vikas Prasad, MD
Associate Professor of Radiology

Richard Tsai, MD
Assistant Professor of Radiology

Liang Wang, MD, PhD
Assistant Professor of Radiology

2022: An MRI Space Odyssey

MIR completed a 3T MRI scanner renovation to incorporate a "Space Invasion" theme in efforts to bolster pediatric studies. The space design mirrors the theme of the mock scanner, providing consistency and comfort for children receiving scans. These efforts will support a multitude of pediatric imaging projects, including the 25-site HEALthy Brain and Child Development Study.

Andy Bierhals Named Vice Chair of Community Radiology

Andrew J. Bierhals, MD, professor of radiology, has been named vice chair for community radiology. Bierhals will oversee and provide clinical services at the community hospitals served by MIR and will work to expand and improve the clinical practice, among other responsibilities. He will continue to serve as director of cardiothoracic imaging at Barnes-Jewish West County Hospital, medical director for CT at the Center for Clinical Imaging Research and MIR's vice chair for quality and safety.

Notably, he helmed MIR's safety response to the COVID–19 pandemic and continues to work to ensure patient and employee safety. He also helped secure grant funding to establish a dedicated follow-up program to limit diagnosis delays for patients with incidental imaging findings.

Bierhals, who joined MIR faculty in 2006, earned his medical degree and a master's degree in public health at the University of Pittsburgh before completing a diagnostic radiology residency and cardiothoracic imaging fellowship at MIR.

Promotions

Tabassum Ahmad, MD
Associate Professor of Radiology

Krystle Barhaghi, MD
Assistant Professor of Radiology

Adam Q. Bauer, PhD
Associate Professor of Radiology

Ganesh B. Chand, PhD
Assistant Professor of Radiology

George M. Cyriac, MD
Assistant Professor of Radiology

Adam T. Eggebrecht, PhD
Associate Professor of Radiology

Cihat Eldeniz, PhD
Assistant Professor of Radiology

J. Daniel Giardina, MD
Associate Professor of Radiology

Daniel P. Harwood, MD
Assistant Professor of Radiology

Joseph E. Ippolito, MD, PhD
Associate Professor of Radiology

Yongjian Liu, PhD
Professor of Radiology

Vincent M. Mellnick, MD
Professor of Radiology

Joyce C. Mhlanga, MD
Associate Professor of Radiology

Maria Rosana Ponisio, MD
Associate Professor of Radiology

Constantine A. Raptis, MD
Professor of Radiology

Demetrios A. Raptis, MD
Associate Professor of Radiology

Martin N. Reis, MD
Associate Professor of Radiology

Courtois and Hedgepeth Named Chiefs



Mallinckrodt Institute of Radiology (MIR) has named Constance S. Courtois, MD, and Bruce L. Hedgepeth, MD, chiefs of radiology at two of MIR's community hospitals. In their new roles, they work to deliver, improve and expand clinical services.

Courtois serves as chief of radiology at Barnes-Jewish St. Peters Hospital, where she has been an assistant professor since 1997. Her clinical and research interests include interventional and cardiovascular radiology, gallstone removal and atrial fibrillation. Hedgepeth serves as chief of radiology at Phelps Health in Rolla, Missouri, where he has worked since 2019. His clinical interests include breast imaging and nuclear medicine.

New MIR Clinic Facilitates Patient-Physician Dialogue

The Patient Care Clinic, located on the lower level of MIR Tower, is a new outpatient clinic. Abdominal, chest, IR, neuro IR and MSK sections will see patients for pre-procedural consultations and post-procedure follow-up. The clinic provides an environment that will help facilitate a comfortable and productive patient-physician dialogue.

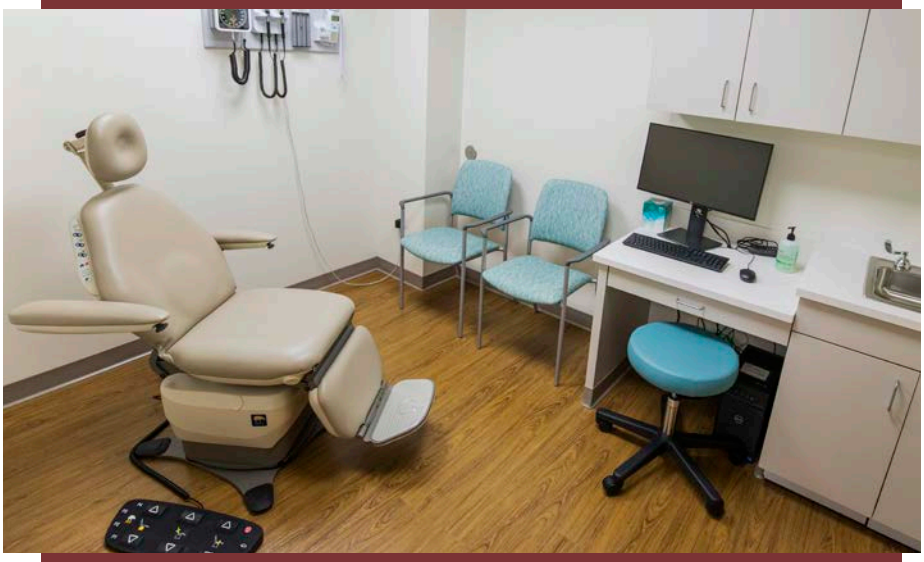

Grants

Janine D. Bijsterbosch, PhD, assistant professor of radiology, received a $477,943 R01 grant from the National Institute of Mental Health. The aim of her project, "Individualized brain biomarkers of late-life depression: contributions to heterogeneity and resilience," is to study depression heterogeneity, risk and resilience using computational models.

Aimilia Gastounioti, PhD, assistant professor of radiology, and **Patrícia M. Ribeiro Pereira, PhD**, assistant professor of radiology, were each awarded a portion of the $1.4 million in new grants from Siteman Cancer Center at Barnes-Jewish Hospital and Washington University School of Medicine in St. Louis for "Advancing Breast Cancer Risk Assessment among White and Black Women Using Artificial Intelligence and Sequential Mammograms" and "The Role of Caveolin-1 in Gastric Cancer Response to Immunotherapy," respectively.

Abhinav K. Jha, PhD, assistant professor of radiology, received a $526,222 grant from the National Institute of Biomedical Imaging and Bioengineering (NIBIB) to develop and comprehensively validate ultra-low count quantitative SPECT (ULC-QSPECT) methods for alpha particle radiopharmaceutical therapies. He was also awarded a $314,807 grant from NIBIB to study AI-based quantitative imaging in clinical decision-making and its ethical applications.

Patrícia M. Ribeiro Pereira, PhD, assistant professor of radiology, received a $100,000 Nuclear Medicine Pilot Research Grant In Neuroendocrine Tumors from the Neuroendocrine Tumor Research Foundation. The two-year award will fund her project "Improving imaging and radiotherapy of nets by endocytic modulation of somatostatin receptors," which aims to develop more effective treatments for neuroendocrine cancers.

The Thirtieth Annual G. Leland Melson Memorial Lecture

Lecture speaker Ivan Pedrosa, MD, PhD (left), with Vincent M. Mellnick, MD, chief of abdominal imaging.

Ivan Pedrosa, MD, PhD, professor of radiology at University of Texas Southwestern Medical Center, presented "Management of Renal Masses with the Clear Cell Likelihood Score" at the 30th annual G. Leland Melson Memorial Lecture in November. His translational genitourinary cancer research focuses on implementing novel quantitative imaging techniques to predict aggressiveness, angiogenesis, immunogenesis and responsiveness to novel therapies, particularly in MRI. Pedrosa also serves as the Jack Reynolds, MD, Chair in Radiology, vice chair of radiology research and co-director of the Harold C. Simmons Comprehensive Cancer Center's Kidney Cancer Program.

Informatics Showcase

MIR hosted the National Cancer Institute's Informatics Technology for Cancer Research (ITCR) investigators at a meeting on September 12-15, where the latest advances in informatics and computational tools for cancer research and precision medicine were showcased. Kooresh I. Shoghi, PhD, professor of radiology, coordinated the event and Siteman Cancer Center served as co-host.

Honors/Awards

James R. Duncan, MD, PhD, professor of radiology, was named a 2022-24 Carol B. and Jerome T. Loeb Teaching Fellow. The two-year fellowship aims to advance education at Washington University School of Medicine in St. Louis by granting dedicated time to focus on implementing innovative ideas to enhance medical students' and residents' education. Duncan's project aims to equip trainees with skills and strategies to prevent errors and respond to obstacles they might encounter while performing common, image-guided procedures.

James R. Duncan, MD, PhD, professor of radiology, and **Pamela K. Woodard, MD**, the Hugh Monroe Wilson Professor of Radiology, were inducted into the Academy of Educators at Washington University School of Medicine in St. Louis. The academy is an institutional collaboration that fosters excellence in health science education, including programs, workshops, grants and awards to support its members' skill development and educational growth.

James R. Duncan, MD, PhD, professor of radiology, **Mariam A. Malik, MD**, assistant professor of radiology, and **Benjamin S. Strnad, MD**, assistant professor of radiology, were selected to participate in the Academy of Educators at Washington University in St. Louis' Teaching Scholars Program. This 12-month program is designed to develop the knowledge and skills of future health-care education leaders with a focus on educational scholarship and curriculum development.

William D. Middleton, MD, professor of radiology, won the Laurence A. Mack Lifetime Achievement Award from the Society of Radiologists in Ultrasound. This award recognizes a career of outstanding achievement in ultrasound research and is presented to society fellows who are leaders in the field and have made significant contributions and advancements.

Ashwin Singh Parihar, MD, instructor in radiology, was named an inaugural Academy Council of Early Career Investigators in Imaging (CECI^2) and Quantitative Imaging Biomarkers Alliance (QIBA) Fellow. Supported by the Academy for Radiology & Biomedical Imaging Research and RSNA, the fellowship offers early-career investigators the opportunity to be mentored by industry experts, contribute to specific QIBA biomarker committees and engage with quantitative imaging experts.

A New Cyclotron for MIR

GE Healthcare PETtrace™ 890 is MIR's latest addition to its Cyclotron & Nuclear Pharmacy. Featuring the most advanced technology, this leading-edge cyclotron will produce a diverse group of isotopes, including O-15, N-13, C-11, Ga-68, F-18, Cu-64 and Zr-89.

FOCAL SPOT

FS

Non-Profit Organization
U.S. Postage PAID
St. Louis, Missouri
Permit No. 2535

Address Service Requested

Washington University in St. Louis
School of Medicine

MIR Mallinckrodt Institute of Radiology

Campus Box 8131
660 S. Euclid Avenue
St. Louis, MO 63110

mir.wustl.edu

MIR attendees connected with radiology peers and presented research and clinical findings at the 2022 RSNA annual meeting in Chicago.